



Available online at  
**ScienceDirect**  
[www.sciencedirect.com](http://www.sciencedirect.com)

Elsevier Masson France  
**EM|consulte**  
[www.em-consulte.com/en](http://www.em-consulte.com/en)



REVIEW

# Ablation of supraventricular arrhythmias in adult congenital heart disease: A contemporary review

*Ablation des arythmies supraventriculaires sur cardiopathie congénitale à l'âge adulte : revue des résultats et des indications actuelles*

Nicolas Combes<sup>a,\*</sup>, Nicolas Derval<sup>b</sup>,  
Sebastien Hascoët<sup>c</sup>, Alexandre Zhao<sup>d</sup>, Denis Amet<sup>d</sup>,  
Mathieu Le Bloa<sup>a,b</sup>, Alice Maltret<sup>e</sup>, François Heitz<sup>a</sup>,  
Jean-Benoit Thambo<sup>b</sup>, Eloi Marijon<sup>d,f</sup>

<sup>a</sup> Paediatric and Adult Congenital Heart Disease Department, Arrhythmias Unit, Clinique Pasteur, 45, avenue de Lombez, 31070 Toulouse, France

<sup>b</sup> Paediatric and Adult Congenital Heart Disease Department, Haut-Lévêque Hospital, Pessac, France

<sup>c</sup> Congenital Heart Disease Department, Hôpital Marie-Lannelongue, Le Plessis-Robinson, France

<sup>d</sup> Département de Cardiologie, Centre de Recherche Cardiovasculaire de Paris (INSERM U970), Hôpital Européen Georges-Pompidou, Paris, France

<sup>e</sup> Department of Paediatric Cardiology, Necker Hospital, Paris, France

<sup>f</sup> Université Paris Descartes, Paris, France

Received 3 November 2016; received in revised form 3 January 2017; accepted 3 January 2017

## KEYWORDS

Catheter ablation;  
Tachycardia;  
Supraventricular;  
Congenital heart defect

**Summary** Supraventricular arrhythmias are an important and increasing cause of morbidity in adults with congenital heart disease, requiring specific management strategies. Pharmacological treatment has limited efficacy, and is often associated with some side-effects. Major improvements in catheter ablation techniques have opened new opportunities to better understand underlying mechanisms of supraventricular arrhythmias, offer better therapy, and eventually improve symptoms and quality of life in these patients. An array of tools and

*Abbreviations:* ACHD, adult congenital heart disease; AF, atrial fibrillation; AP, accessory pathway; CHD, congenital heart disease; IART, intra-atrial reentrant tachycardia; SVA, supraventricular arrhythmia.

\* Corresponding author.

E-mail address: [n.combes@clinique-pasteur.com](mailto:n.combes@clinique-pasteur.com) (N. Combes).

<http://dx.doi.org/10.1016/j.acvd.2017.01.007>

1875-2136/© 2017 Elsevier Masson SAS. All rights reserved.

techniques are necessary to access relevant anatomical areas to address the arrhythmogenic substrate. The mechanism of these arrhythmias is mostly related to macroentry around surgical scars or cavotricuspid isthmus-dependent flutter. The efficacy of catheter ablation is mainly dependent on the underlying congenital heart condition, with the most complex cases typically being associated with atrial switch and Fontan surgeries. Although relatively high rates of recurrence are seen after a single procedure, additional attempts are often helpful to decrease recurrences and improve symptoms. Catheter ablation in such patients continues to present many unique challenges that are best addressed by experienced multidisciplinary teams, at centres equipped with the proper catheters, imaging capabilities, mapping systems and support staff needed to maximize safety and success. Consensus indications have emerged that often support ablation as first-line therapy in these patients. In this comprehensive review, we aim to describe the specific issues associated with ablation of supraventricular arrhythmias in adult congenital heart disease, assess the results in contemporary practice and, finally, review the current indications.

© 2017 Elsevier Masson SAS. All rights reserved.

## MOTS CLÉS

Ablation par cathéter ;  
Tachycardie ;  
Supraventriculaire ;  
Cardiopathie congénitale

**Résumé** Les arythmies supraventriculaires sont une cause importante et croissante de morbidité chez les adultes porteurs d'une cardiopathie congénitale. Elles nécessitent une prise en charge spécifique. Le traitement médical a une efficacité limitée et reste associé à des effets secondaires significatifs. Les progrès majeurs de l'ablation par cathéters apportent de nouvelles données sur les mécanismes de ces arythmies, permettent de les traiter en améliorant les symptômes et la qualité de vie. Le mécanisme est le plus souvent une macrorentrée dépendante de l'isthme cavo-tricuspidien ou d'une large cicatrice. L'efficacité de l'ablation par cathéter est dépendante de la cardiopathie sous-jacente. Les cas les plus complexes sont représentés par les switch atriaux et les chirurgies de Fontan. Malgré des récives après une première procédure, des reprises peuvent être proposées pour améliorer le succès à long terme et les symptômes. L'ablation des arythmies supraventriculaires chez ces patients comporte beaucoup de challenges et spécificités. Elle sera au mieux réalisée par des équipes multidisciplinaires expérimentées, dans des centres équipés des différentes modalités d'imagerie et de cartographie avec différents types de cathéters disponibles afin de diminuer le risque de complication et d'améliorer les résultats. Des indications consensuelles ont été proposées, positionnant souvent l'ablation en première intention chez ces patients. Nous décrivons dans cette revue les particularités de l'ablation des tachycardies supraventriculaires chez les adultes porteurs de cardiopathie congénitale, les résultats actuels et les indications retenues.

© 2017 Elsevier Masson SAS. Tous droits réservés.

## Background

The prevalence of adults with congenital heart disease (CHD) has been increasing continuously over the past decades, with improved surgical and interventional procedures leading to better survival. Nowadays, adults with complex CHD account for 60% of all patients with CHD [1]. Nevertheless, even in simple CHD, life expectancy remains lower than in the general population.

Arrhythmias, including supraventricular arrhythmias (SVAs), form an important component in the care of adult CHD (ACHD). Even by 2009, data from the USA had indicated that SVAs occur in 15% of adults with CHD. Furthermore, the prevalence of SVA increases with age, and >50% of patients with severe CHD who reach the age of 18 years go on to develop atrial arrhythmias by the age of 65 years [2]. SVA incidence and type are dependent on the

underlying CHD (Table 1). SVAs are associated with a near 50% increase in mortality. The risk of stroke and heart failure is twice as high as in an age/sex-matched general population. Arrhythmias are also the main cause of emergency admissions [3]. The relationship between SVA and sudden death has been well demonstrated in Wolff-Parkinson-White syndrome [4]. SVAs may rapidly provoke poor haemodynamics in ACHD, as in transposition of the great arteries and atrial switch. SVAs with relatively slow cycle lengths can be conducted to the ventricle in a 1:1 fashion with poor tolerance [5]. The occurrence of SVAs is favoured by surgical atrial scar, pressure or volume overload of cardiac chambers, accessory atrioventricular pathways or dual/atrioventricular node physiology. Mostly, they are related to intra-atrial reentrant tachycardia (IART) around surgical scars or natural anatomical barriers, such as cavotricuspid isthmus-dependent flutter. The incidence of atrial

**Table 1** Supraventricular arrhythmia types and contemporary relative incidence in the main forms of adult congenital heart disease.

Type of ACHD	IART	AP	AF	Atypical AVNRT
ASD	+++		++	+ (primum ostium)
VSD	+			
AVCD	++		+	+
Congenital aortic stenosis and coarctation			++	
TOF	++		+	
dTGA and atrial switch	+++		+	
Ebstein's anomaly	++	+++		
ccTGA	+ (++ with double switch)	++	+	+
Fontan surgery with atriopulmonary connection	++++		+	+
TCPC	++			+

ACHD: adult congenital heart disease; AF: atrial fibrillation; AP: accessory pathway; ASD: atrial septal defect; atypical AVNRT: atypical atrioventricular nodal reentrant tachycardia with variant location or twin atrioventricular node; AVCD: atrioventricular canal defect; ccTGA: congenitally corrected transposition of the great arteries; dTGA: d-transposition of the great arteries; IART: intra-atrial reentrant tachycardia; TCPC: total cavopulmonary connection; TOF: tetralogy of Fallot; VSD: ventricular septal defect.

fibrillation (AF) increases with age and CHD complexity [6].

The treatment of SVAs in ACHD remains challenging, and clinical experience indicates that pharmacological treatment is of limited efficacy. Studies objectively evaluating the efficacy of medical treatment in this setting are still scarce. Flecainide is associated with a risk of proarrhythmia in patients with cardiomyopathy [7], and its safety – with potential unstable haemodynamics, as in the majority of complex CHDs – is questionable. Amiodarone has many long-term systemic effects [8], and is therefore undesirable in young patients with ACHD. Moreover, rhythm control efficacy seems lower in ACHD [9]. Considering the above facts, percutaneous catheter ablation holds great promise with regards to definitive and potentially curative treatment. Nevertheless, the challenging anatomy, further compounded by previous surgery, often leads to a need for complex procedures that must be handled by multidisciplinary experienced teams.

## General consideration of percutaneous ablation of arrhythmias in CHD

Since the early 1990s, percutaneous catheter ablation of arrhythmias in ACHD has expanded with improvements in knowledge and technology, leading to better efficacy. Three-dimensional mapping systems allow volume reconstruction with real-time navigation of the ablation catheter in three-dimensional spaces, and are of particular interest in those patients with complex anatomy. Anatomical landmarks such as the atrioventricular groove and venous connexions can be precisely located and marked. The position of the conduction network, frequently displaced in CHD [10], can be tagged to avoid damage during ablation. Voltage maps allow delineation of areas of scars that can be the substrate of arrhythmias. Activation maps can show the arrhythmia circuit and help to find the ablation target. Remote magnetic navigation may be helpful to increase

catheter manoeuvrability and stability, and to decrease fluoroscopic time in patients with limited access and mapping difficulty [11,12]. The quality of ablation lesions can be improved by the use of irrigated catheters [13] and contact force monitoring [14]. Cryoablation can also be of value to increase the safety of the ablation when working close to the atrioventricular node or coronary arteries [15]. Interventional techniques have emerged to allow access to the critical substrate with transbaffle punctures [16], transconduit punctures [17], transhepatic venous access [18] or transthoracic access [19]. Transseptal access after septal closure devices can also be performed [20]. Three-dimensional transoesophageal echocardiographic guidance may be useful for punctures. Surgical ablation also has its role, mostly performed concomitantly with other surgery to improve haemodynamics [21]. Case-by-case multidisciplinary input is required to choose the best option in CHD patients.

## Ablation of atrioventricular tachycardia

Atrioventricular tachycardias include atrioventricular reentrant tachycardia, related to an accessory pathway (AP), as well as atrioventricular nodal reentrant tachycardia with single or twin atrioventricular nodes. It appears that despite the difficulties of unusual anatomical landmarks and abnormally positioned conduction systems, most APs and slow pathways in ACHD can be safely and effectively ablated. Catheter ablation is therefore generally preferred over long-term antiarrhythmic drug therapy. A recently published consensus document [22] has recommended catheter ablation for recurrent symptomatic and/or drug-refractory supraventricular tachycardia related to accessory atrioventricular connections or twin atrioventricular nodes in symptomatic ACHD, for ventricular preexcitation and high-risk or multiple APs, as commonly encountered in Ebstein's anomaly, and/or drug-refractory atrioventricular nodal reentrant tachycardia (Table 2).

**Table 2** Proposed indications for percutaneous ablation of supraventricular tachycardias in adult congenital heart disease.

1. Preoperative electrophysiological testing/ablation of AP or double atrioventricular node, where vascular or cardiac chamber access is restricted after surgery
2. Systematic electrophysiological testing of manifest AP associated with ACHD and ablation in first-line therapy in cases of multiple APs and/or short refractory period; ablation can be proposed in cases of inducible supraventricular tachycardia alone and easy access to the pathway
3. Atrioventricular reentrant tachycardias with AP, intranodal mechanism or twin atrioventricular node with haemodynamic compromise in first-line therapy
4. Recurrent symptomatic atrioventricular tachycardia with AP, intranodal mechanism or twin atrioventricular node with easy access to dedicated cardiac chamber in first-line therapy or after failure of medical therapy in complex anatomy or limited vascular access
5. Recurrent symptomatic IART in first-line therapy; discussion of first-line medical therapy (rhythm or rate control) in complex anatomy/difficult access to cardiac chamber
6. In AF refractory to medical treatment, pulmonary venous antrum electrical isolation is recommended in selected cases after discussion of rhythm versus rate control
7. Ablation of atrioventricular junction with permanent pacemaker implantation in selected cases with supraventricular permanent arrhythmias associated with symptoms of heart failure and insufficient rate control

ACHD: adult congenital heart disease; AF: atrial fibrillation; AP: accessory pathway; IART: intra-atrial reentrant tachycardia.

### Atrioventricular reentrant tachycardia

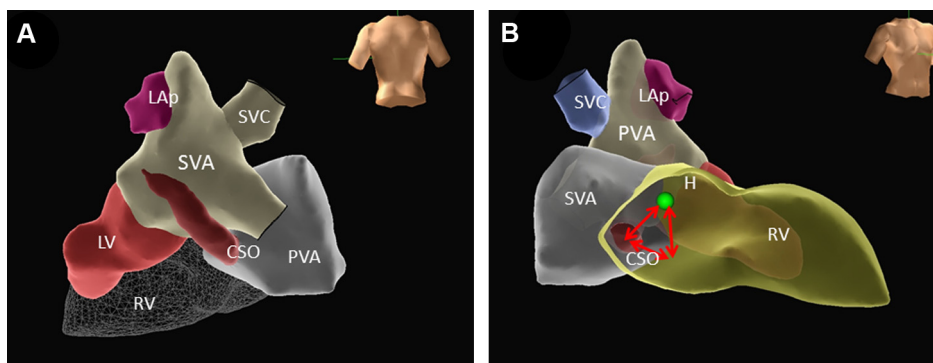
Whereas catheter ablation of atrioventricular reentrant tachycardia is feasible in most patients with CHD, short- and long-term success rates are lower than similar procedures performed in patients with normal cardiac anatomy. The acute success rate is about 80–85%, and the recurrence risk is as high as 15–20% [23]. Complication rates remain reasonable (5%), although they are estimated to be approximately twofold higher compared with non-CHD procedures. It is generally agreed that attempts should be made to ablate such pathways ahead of any surgical correction, as catheter access to an area of interest may become difficult following repair, and intraoperative AP interruption during subsequent surgery may be offered as a second-line option in case of failure. APs are associated with a variety of CHDs (Table 1), most frequently with Ebstein's anomaly and congenitally corrected transposition of the great arteries. Acquired APs can also be encountered exceptionally in patients with modified Fontan surgery (Bjork's surgery) with atriopulmonary connection for tricuspid atresia [24]. The electrophysiology of the APs in patients with CHD is not unique. However, the physiological and clinical implications of the tachycardia may be markedly different in these patients. Abnormal anatomy and atypical conduction systems may also enhance the difficulty and risks of catheter ablation. In addition, electrocardiogram localization algorithms may be misleading, and should be interpreted with caution in CHD [25]. Although Ebstein's anomaly accounts for < 1% of all CHDs, the prevalence of APs in patients with this anomaly is much higher than in other CHDs [26]. Approximately 25% of patients with Ebstein's anomaly have an AP (mostly manifest AP), and they are prone to having multiple APs (up to 50% of cases). A right bundle branch block pattern is typically present because of posteroseptal conduction delay, and its absence should raise suspicion of the presence of an AP. The localization of APs (usually right-sided and located along the posterior part of the dysplastic

portion of the tricuspid annulus) is often difficult because of a massively enlarged right heart, the expanded tricuspid annulus region caused by displacement of the tricuspid valve and distortion of anatomical landmarks, all of which can make catheter stability difficult [27]. Overall, catheter ablation is particularly challenging, and has an estimated success rate of about 75% in experienced centres. Special long sheaths are often required, and different techniques can be used to visualize the true atrioventricular groove, including selective angiography or intracoronary mapping of the right coronary artery. The use of three-dimensional navigational tools or intracardiac echocardiographic guidance may be helpful in these cases. In Ebstein's anomaly, catheter ablation carries an increased risk of coronary injury because of the thin atrialized portion of the right ventricle adjacent to the atrioventricular groove. The use of cryoenergy may lower this risk, and has advantages for catheter stability because of the cryoadherence of the ablation catheter tip.

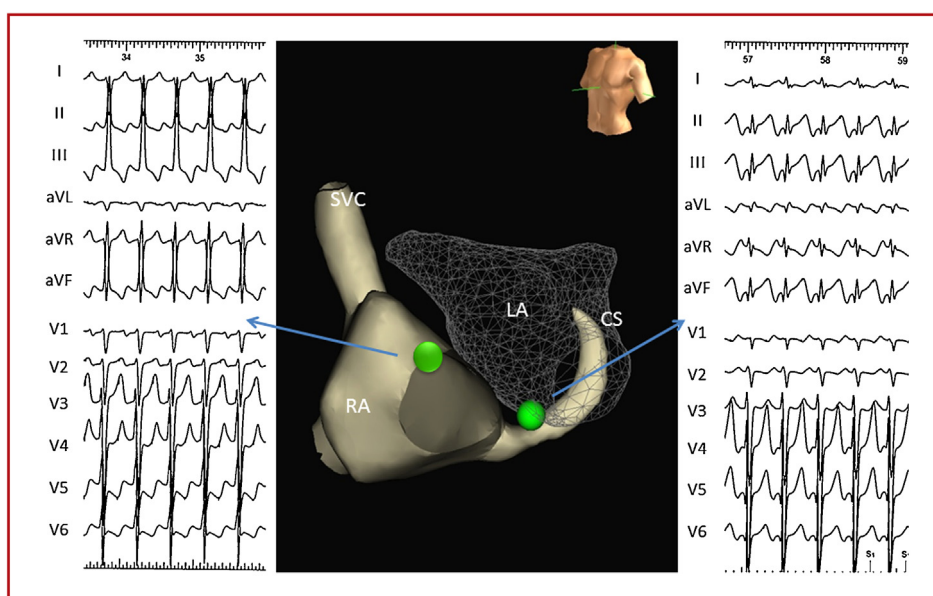
APs are found in 2–5% of patients with congenitally corrected transposition of the great arteries, and are typically located along the left-sided atrioventricular valve annulus, which is the anatomical tricuspid valve. During the procedure, the coronary sinus serves as an important anatomical landmark for the orientation of the tricuspid valve.

### Atrioventricular nodal reentrant tachycardia

The variations in anatomical locations as well as the possibility of "twin" atrioventricular nodes represent unique aspects of atrioventricular nodal reentrant tachycardia in ACHD. Indeed, patients with CHD have less predictable atrioventricular node locations [10]. In patients with atrioventricular canal defects, for instance, the node develops outside the triangle of Koch in a region inferior to the mouth of the coronary sinus, whereas in those with congenitally corrected transposition of the great arteries, the atrioventricular node is usually displaced to a superior location medial to the right atrial appendage. The atrioventricular



**Figure 1.** Three-dimensional navigation system reconstruction of the triangle of Koch after Mustard surgery for d-transposition of the great arteries. A. Posterior view showing the relationship between new atrial cavities and vessels. B. Location of the triangle of Koch with sinus ostium positioned in the left side of the atrial baffle, needing left approach for atrioventricular nodal tachycardia ablation. CSO: coronary sinus ostium; H: His bundle location; LAP: left atrial appendage; LV: left ventricle; PVA: pulmonary venous atrium; RV: right ventricle; SVA: systemic venous atrium; SVC: superior vena cava.



**Figure 2.** Twin atrioventricular node location with three-dimensional navigation system in a patient with congenitally corrected transposition of the great arteries, large ventricular septal defect and pulmonary stenosis. Ventricular activation by each node produces a different ventricular electrocardiogram pattern of activation. CS: coronary sinus; LA: left atrium; RA: right atrium; SVC: superior vena cava.

node may also be left-sided in some patients with dextrocardia or heterotaxy syndrome. Even if the node is not actually displaced, the landmarks for the triangle of Koch will be distorted in conditions such as tricuspid atresia, Ebstein's anomaly or abnormalities of the coronary sinus. Furthermore, surgical patching can complicate catheter positioning near the nodal extensions after the Mustard or Senning operation for d-transposition of the great arteries (Fig. 1) or after the Fontan operation for single ventricle [28]. Careful attention must be given to locating the normal conduction system, which cannot be mapped precisely in up to 10% of single ventricles, and therefore precludes radiofrequency ablation. Atrioventricular reciprocating tachycardia mediated by twin atrioventricular nodes can be a source of recurrent supraventricular tachycardia in complex CHD (especially in congenitally corrected transposition of the great arteries, atrioventricular canal defect and right isomerisms) [29]. It

consists of an anterior atrioventricular node and His bundle at the right atrial-mitral annulus junction, and a second posterior atrioventricular node and His bundle close to the remnant of the inferior interatrial septum, sometimes in the left-sided atria (Fig. 2). The diagnosis can be suspected from a surface electrocardiogram if spontaneous alternations of superior and inferior QRS-axis are noted in the basic rhythm. During the electrophysiological study, pacing from different atrial sites, programmed ventricular stimulation during atrioventricular reentrant tachycardia and careful mapping of the entire atrioventricular groove can be used to objectively identify two distinct and separate areas with His bundle signals. The atrioventricular nodal system with reduced conduction capacity typically serves as the retrograde limb of the interatrioventricular nodal reentry tachycardia, and is targeted in most cases. Clearly, an extensive understanding of the anatomy and electrophysiology

should be obtained in such patients before proceeding to ablation. Furthermore, a lack of clarity in defining the anatomy of atrioventricular conduction in these patients suggests that the ablation should first be undertaken using cryotherapy, which can facilitate cryomapping before the definitive ablation to avoid any damage to the conducting system in cases of inappropriate location of the ablation catheter. Radiofrequency energy can be used in cases of unsuccessful cryoablation or after a recurrence. The one caveat to this recommendation is that low-power radiofrequency application may be helpful in identifying the location of the anterior and posterior atrioventricular nodes through the occurrence of accelerated junctional rhythm.

## Ablation of atrial tachycardia

Atrial tachycardias include IART, focal atrial tachycardia and AF. Specific management strategies are recommended in ACHD [22]. Anticoagulation indications are broader than those advised for the general population, and are recommended not only for patients with a CHA<sub>2</sub>DS<sub>2</sub>-VASc (Cardiac failure, Hypertension, Age  $\geq$  75 [Doubled], Diabetes, Stroke [Doubled]—Vascular disease, Age 65–74 and Sex category [Female]) score  $\geq$  2, but also for moderate to complex CHD or significant valve disease in simple CHD. For rhythm control, based on the low success of medical treatment, percutaneous ablation should be considered early in the course (Table 2). In cases of ablation failure, poor tolerance or difficulties with rate control, atrioventricular node ablation should be discussed for management of permanent atrial tachycardias. A case-by-case discussion is mandatory in this setting, considering the difficulties of permanent pacemaker implantation in ACHD, with restricted access to cardiac chambers, residual shunts and risks of surgical approach.

## IART

IART generally represents the major indication for arrhythmia ablation in CHD. Although most studies on ablation of IART in CHD are single centre, with a limited number of patients, and spread across a large spectrum of CHD conditions, nevertheless, some important data can be gleaned. Larger and more recent series in this regard are reported in Table 3 [30–43]. Overall, the acute success rate is good (76–96%), being higher for cavotricuspid isthmus-dependent tachycardia than other forms of IART. The definition of success varies between series from only interruption of tachycardia to non-inducibility. In fact, the validation of electrical block in the isthmus of the tachycardia is an important goal, associated with lower recurrences [44]. Targeting all inducible tachycardias is more difficult, but is associated with better long-term outcomes. Success rates increase with the use of improved technologies, including irrigated radiofrequency catheters and the utilization of three-dimensional mapping/reconstruction, which are currently the gold standard approaches. The success rate is also associated with the type of CHD. Simple CHDs (atrial and ventricular septal defect, tetralogy of Fallot) with no cardiac chamber access problems have the highest acute success rate (close to 90%). Most arrhythmia

circuits are localized in the right atrium. Often, multiple IART circuits are seen in the same patient, with a high prevalence of cavotricuspid isthmus-dependent macroreentry. Scar-related IART is more frequently located around the right atriotomy, less frequently around cannulation scars and rarely around septal patches/sutures. Recurrences occur in 20–30% of these patients at mid-term follow-up. These results are inferior to regular ablation in a structurally normal heart with common atrial flutter, where an acute success rate of about 98% and recurrence rate of about 10% are commonly observed [45]. However, they are similar to the success encountered in complex ablation procedures in the structurally normal heart, such as paroxysmal AF ablation, with a mean long-term success rate of around 50% after a single procedure [46]. Complex CHD surgeries (atrial switch with Mustard or Senning procedure, Fontan surgery and total cavopulmonary connection with lateral tunnel for univentricular hearts), frequently associated with difficult access to the cardiac chamber of interest, have the lowest success rates, varying between 40% and 83% in the latest series. Large scarring in atrial switch and Fontan surgery with atriopulmonary anastomosis are associated with a higher incidence of IART and a higher number of circuits in the same patient (Fig. 3). In the case of Fontan surgery with atriopulmonary connection, the pressure overload of the right atrium is associated with a thick and much enlarged myocardium that complicates the delivery of the transmural radiofrequency lesion necessary to interrupt the tachycardia isthmus. Recurrences are also more frequent (up to 54%) at mid-term follow-up. Different techniques using transbaffle/conduit punctures are frequently necessary. Remote magnetic navigation can help the arrhythmia substrate to be reached in these cases. Acute complication rates associated with such an intervention are low in experienced hands (between 0% and 17%; possibly under reported), but are potentially life-threatening. These event rates are similar to those observed in other complex ablations, such as ventricular tachycardia ablation in structural heart disease [47,48]. Classically, the most frequent complications are groin haematoma and local bleeding. Thromboembolic events can occur, and require close monitoring of anticoagulation before, during and after the procedure. Rare cardiac perforations have been described, with pericardocentesis and two cases of surgical repair. Atrioventricular node or His bundle damage can lead to pacemaker implantation, which can be rendered challenging because of complex anatomy. A particular complication in these patients is worsening cyanosis, particularly after transbaffle/conduit puncture; it can require specific management, and a close follow-up seems to be recommended in these cases. Rarely, injury to pacemaker leads can occur, requiring replacement. Rare acute kidney injury and low cardiac output require transient haemodynamic support and dialysis. No periprocedural death has been reported so far, but some arrhythmias with haemodynamic compromise require direct-current shocks, highlighting the need for close haemodynamic monitoring during such a procedure. Despite recurrences, a large number of patients remain in sinus rhythm, with clinical improvement, assessed in some studies by clinical scoring [42]. New IARTs can occur during follow-up. Repeated procedures are associated with fewer mid-term recurrences, and should be proposed in selected symptomatic cases.

**Table 3** Main studies of percutaneous ablation of intra-atrial reentrant tachycardias in adults with congenital heart disease.

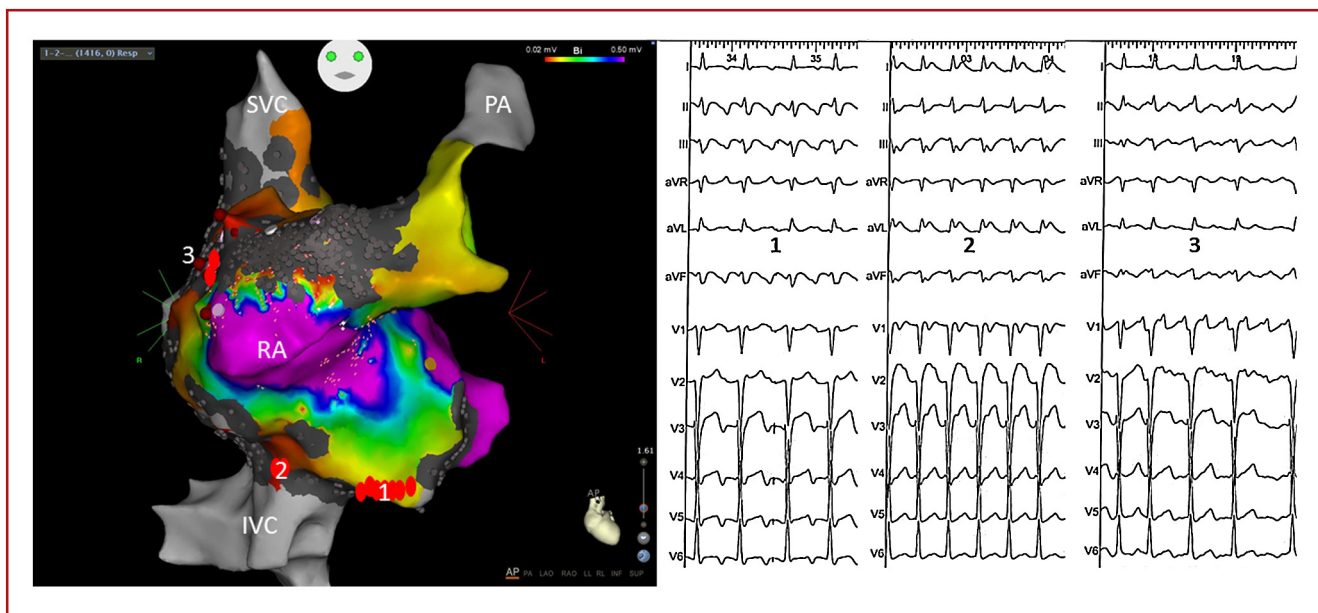
First author (date)	Patients (n)	Type of CHD	Age (years)	Type of tachycardia (n)	Technique	Endpoint	Acute success (%)	Number (%) of complications	Follow-up (months)	Recurrences (%)
Hebe (2000)	69	ASD, VSD, AVCD, Ebstein, TOF, ASw, Fontan, others	29.4 ± 18.6	IART (80), CTI (25), AT (8)	3D, RF	Stop tachycardia	75	None	21	11
Triedman (2002)	134	TOF, VSD, ASD, Ebstein, Fontan, TCPC, ASw, others	25.3 ± 12.2	IART	IRF (39), 3D (69)	Stop tachycardia	79	22 (16)	25	43
Blafox (2002)	31 (8 CHD)	Fontan, ASw, others	18 ± 3	IART (14), CTI (8)	3D, IRF and RF	IART non-inducibility	96	NP	0	NP
Kannankeril (2003)	47	Fontan, TOF, ASD, Ebstein, ASw, others	28 ± 13	IART	BC (7), RF	IART non-inducibility	93	None	38	34 (IART), 19 (others)
Tanner (2004)	36	ASD, TOF, Fontan, ASw	46 (9–67)	IART (14), CTI (34), others (4)	3D, IRF	IART non-inducibility	94	1 (2.6)	17	8 (25% AAD)
Lukac (2005)	83	ASD, TOF, ASw, Fontan	47 (9–73)	IART (30), CTI (66), others (17)	3D, RF and IRF	AT non-inducibility	88	None	27	24 (31% AAD)
Seiler (2007)	40	ASD, AVCD, VSD, TOF, ASw, others	52 ± 12	IART (40), CTI (8)	3D, IRF	IART non-inducibility	88	NP	17	3 (42 others)
Yap (2010)	118	ASD, VSD, Fontan, TOF, ASw, VSD, others	40 ± 13	IART	3D, RF or IRF	IART non-inducibility	69	13 (7)	44	48
De Groot (2010)	53	ASD, Fontan, TOF, VSD, Ebstein, ASw, others	38 ± 15	IART (22), CTI (27), AT (5)	3D, RF or IRF	IART termination, CTI isthmus block	65	NP	60	56

**Table 3** (Continued)

First author (date)	Patients (n)	Type of CHD	Age (years)	Type of tachycardia (n)	Technique	Endpoint	Acute success (%)	Number (%) of complications	Follow-up (months)	Recurrences (%)
Drago (2011)	31	ASD, VSD, ASw, Fontan, others	26 ± 17	IART (20), CTI (5), AT (9)	3D, RF and IRF	Non-inducibility of organized tachycardia with isoproterenol	87	None	12	0
Mah (2011)	58	TOF, DORV	35 (1.8–57)	IART (38), CTI (47), AT (16)	3D, RF and IRF	IART termination	96	NP	36	34
Akca (2012)	36	A TOF, ASD, VSD, AVSD, ASw, Fontan, Ebstein, others	35 ± 19	IART (31), AT (25)	3D, IRF, RMN	Non-inducibility	86	3 (8)	26	39
Ueda (2013)	116	ASD, Ebstein, ASw, TOF, VSD, TCPC, Fontan, others	40 ± 15	IART (87), CTI (47), AT (43), others (51)	3D, IRF, RMN	No inducible atrial arrhythmia	86.4	2 (1.3)	20	20.2
Correa (2013)	90	Fontan, TCPC, ASw	26.4 (1.6–55)	IART (78), AT (22), others (64)	NP	NP	81	10 (8.5)	12	27
Correa (2015)	52	TCPC	18.4 ± 11.8	IART (25), AT (8), others (26)	3D, RF, IRF or cryo	Non-inducibility	76	4 (7.7)	18.2	50
Anguera (2015)	111	ASD, TOF, Ebstein, VSD, ASw, others	47 ± 15	CTI (63), IART (50)	3D (70), RF (45), IRF (37)	Isthmus block	88	6 (5.4)	57	41
Moore (2016)	36	TCPC	23 ± 7	IART (21), AT (7), others (6)	3D, RF and IRF	IART non-inducibility	83	8 (17)	4.8	17

3D: three-dimensional mapping system; AAD: antiarrhythmic drug; ASD: atrial septal defect; AT: focal atrial tachycardia; ASw: atrial switch; AVCD: atrioventricular canal defect; BC: basket catheter; CHD: congenital heart disease; CTI: cavotricuspid isthmus-dependent; DORV: double outlet right ventricle; IART: intra-atrial reentrant tachycardia; IRF: irrigated radiofrequency; NP: data not provided; RF: conventional radiofrequency; RMN: remote magnetic navigation; TCPC: total cavopulmonary connection; TOF: tetralogy of Fallot; VSD: ventricular septal defect.





**Figure 3.** Catheter ablation of intra-atrial reentrant tachycardias after Fontan surgery with atriopulmonary connexion for tricuspid atresia. A. Three-dimensional reconstruction with voltage colour-coded map (scar area in grey, normal voltage area in purple). Ablation spots are noted with red dots with three isthmuses for intra-atrial reentrant tachycardia: 1 = cavotricuspid isthmus; 2 = cannulation scar with short isthmus; 3 = isthmus around the atriopulmonary connection. B. Corresponding 12-lead electrocardiogram for each tachycardia related to the three isthmuses. IVC: inferior vena cava; PA: pulmonary artery; RA: right atrium; SVC: superior vena cava.

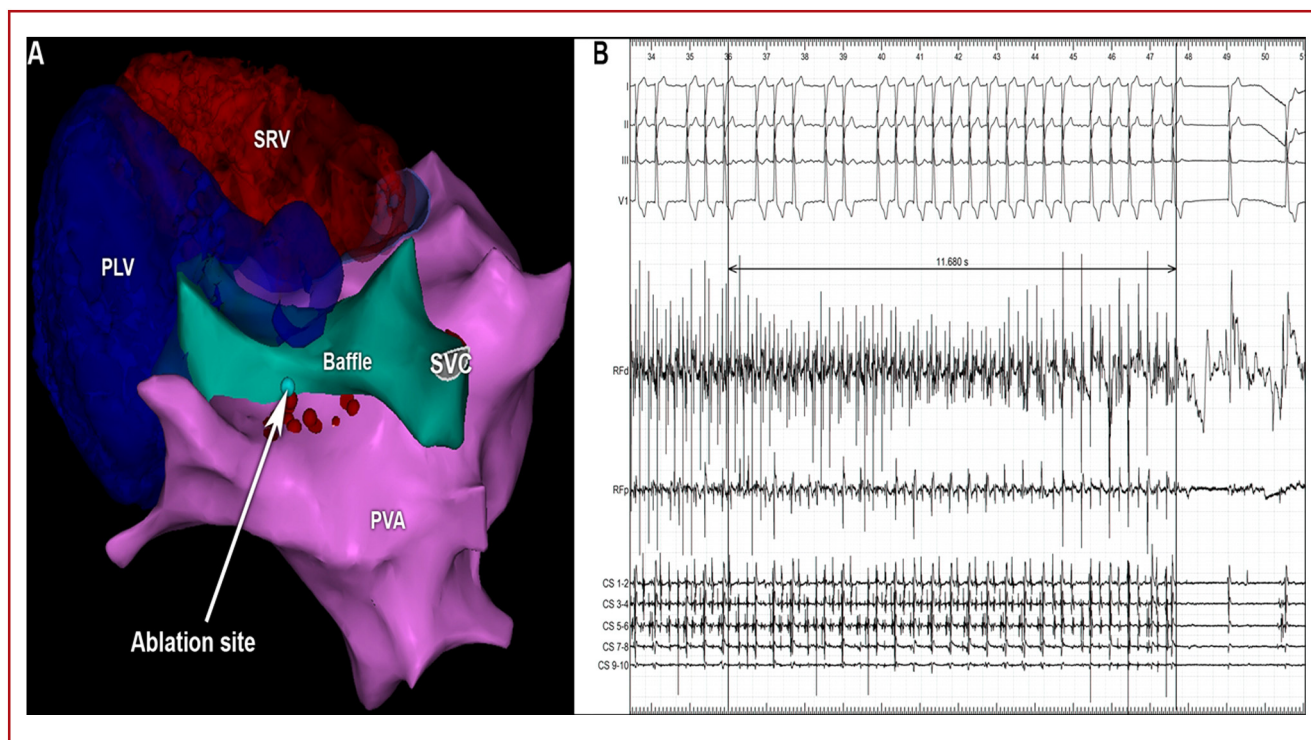
## Focal atrial tachycardia

Focal atrial tachycardia is generally defined as an electrical activation originating from a small, circumscribed region from which it expands centrifugally to the rest of the atria. In this case, there is no wavefront circulating around an anatomical obstacle or a localized atrial scar. The identification of the definite "focal" nature of the tachycardia is therefore conditioned by the spatial resolution of the mapping tool, and the distinction from a small, localized reentry can be sometimes challenging [49]. To date, there has been a limited number of case series describing the precise mechanisms of atrial tachycardia in patients with CHD. However, in the largest and most recently published case series (Table 2), the prevalence of focal atrial tachycardia among the other mechanisms (mainly IART) appears to be relatively low (between 10% and 20%), and is reported in almost all the different types of CHD. The origin of focal atrial tachycardia is classically described from sites near surgical sutures [34,50,51]. de Groot et al. [49] reported focal atrial tachycardia also localized in areas remote from any suture line. In these cases, the presence of low-amplitude fractionated potentials and continuous electrical activity at sites of earliest activation was usually recorded in atrial tachycardia, and abnormal electrograms in sinus rhythm, suggesting the presence of structural abnormalities at sites of focal atrial tachycardia origin, were also seen. However, most of these studies were not performed with high-density mapping catheters, and it would be interesting to revisit the focal nature of atrial tachycardia in CHD with higher spatial resolution. If accurate mapping can be performed, and a clear diagnosis of focal mechanism demonstrated, then radiofrequency ablation is usually highly effective, given the small lesion size required, with an acute success rate of

usually more than 80% (Table 2). There is a reported relatively high rate of long-term SVA recurrence (59%), but recurrence of the originally ablated focal atrial tachycardia remains scarce [34]. Recurrences are mostly caused by a new focus or IART originating from a different location compared with the first ablation procedure.

## AF ablation

AF prevalence in ACHD is reported to be between 25% and 30% [6,52]. Patients with CHD develop AF at a younger age, with a rapid progression from paroxysmal AF to persistent AF. AF is more prevalent in patients with residual left-sided obstructive lesions or unrepaired CHD, and in patients with a history of IART. The relatively low prevalence of AF in adult patients with CHD relates to the fact that most haemodynamic abnormalities and sites of surgical scarring tend to involve right heart structures. The CHDs commonly associated with early AF include aortic stenosis, mitral valve disease and unrepaired single ventricle [52]. Atrial septal defect represents an important population of ACHD with AF because of the high number of patients undergoing late surgery at an advanced age with significant left atrial remodelling [6]. Whereas in non-CHD patients, pulmonary veins are the cornerstone of the AF mechanism, the substrate of AF in ACHD is slightly different. Specific haemodynamic conditions associated with ACHD can influence AF development, with the possibility of right and left atrial sources [53]. Upstream therapy, including treatment of recurrent IART with catheter ablation, and appropriate medical and surgical management of the underlying CHD, is probably important to prevent AF [6]. Cardioversion with a prophylactic antiarrhythmic drug remains the first-line treatment to prevent establishment of permanent AF, which is usually poorly tolerated. In these



**Figure 4.** Catheter ablation of atrial fibrillation in patient with d-transposition of the great arteries and Senning surgery. Conversion to sinus rhythm during ablation at a fragmented site, near a surgical suture line. A. Cranial view of the posterosuperior baffle suture line and ablation site with three-dimensional system reconstruction. B. Electrograms and electrocardiogram during ablation showing organization then conversion to sinus rhythm. PLV: subpulmonary left ventricle; PVA: pulmonary venous atrium; SRV: systemic right ventricle; SVC: superior vena cava.

patients, it is important to identify AF, as it may impact surgical management.

Surgical treatment of AF using the Cox-type Maze procedure should be considered if a patient requires surgery related to haemodynamic management of the CHD [21]. This is especially true in patients with Fontan procedure, where occurrence of AF may prompt consideration of a Fontan conversion (total cavopulmonary connection) associated with a Cox-type Maze procedure. Percutaneous catheter ablation of symptomatic AF should also be seriously considered before percutaneous closure of atrial septal defect in adults, considering the difficulties of left atrial access after septal closure [20]. In other situations, when AF is poorly tolerated, and conservative management (antiarrhythmic drug and cardioversion) is either ineffective or not tolerated, catheter ablation represents an alternative approach (Table 2). Case reports have demonstrated its feasibility and potential efficacy (Fig. 4) [54,55], but further studies are needed to define the role and target of catheter ablation in the setting of rhythm control for AF and complex CHD.

## Conclusions

The SVA burden in ACHD is increasing dramatically, and has been associated with an increase in morbidity and/or mortality; it represents a turning point in the evolution of these patients. Pharmacological treatment has demonstrated

relatively low efficacy with limited tolerance in this setting. With improvements in knowledge of arrhythmia mechanisms and interventional tools, percutaneous catheter ablation has become an important and established treatment for these patients. The efficacy is good, with a low rate of adverse events, and progressive improvements noted over time. Recent guidelines emphasize the role of SVA ablation in ACHD [22]. The main proposed indications are outlined in Table 2. A global approach to the patient with CHD is mandatory, with dedicated teams comprising surgeons, cardiologists and electrophysiologists with specific training and knowledge of CHD, to choose the best option, increase success rates and reduce complications. Newer techniques and tools for these particular procedures with appropriate experience in using them are necessary. Important knowledge gaps remain, with large registries providing data about the impact on quality of life, morbidity and mortality still lacking. Refinement of surgical techniques, with limitation of atrial scars, lowers the incidence of scar-related tachycardias (especially atrial switch for d-transposition of the great arteries and total cavopulmonary connection), but more progress is still needed in this area. Early percutaneous closure of intracardiac shunts without surgery wherever possible (notably atrial septal defect closure) is expected to decrease the long-term SVA burden. The future challenge in these patients is the emergence of AF with increasing incidence associated with ageing, and the limited experience with these specific substrates.

## Disclosure of interest

The authors declare that they have no competing interest.

## References

- [1] Marelli AJ, Mackie AS, Ionescu-Ittu R, Rahme E, Pilote L. Congenital heart disease in the general population: changing prevalence and age distribution. *Circulation* 2007;115:163–72.
- [2] Bouchardy J, Therrien J, Pilote L, et al. Atrial arrhythmias in adults with congenital heart disease. *Circulation* 2009;120:1679–86.
- [3] Kaemmerer H, Bauer U, Pensl U, et al. Management of emergencies in adults with congenital cardiac disease. *Am J Cardiol* 2008;101:521–5.
- [4] Al-Khatib SM, Arshad A, Balk EM, et al. Risk stratification for arrhythmic events in patients with asymptomatic pre-excitation: a systematic review for the 2015 ACC/AHA/HRS guideline for the management of adult patients with supraventricular tachycardia: a report of the American College of Cardiology/American Heart Association Task Force on Clinical Practice Guidelines and the Heart Rhythm Society. *Circulation* 2016;133:e575–86.
- [5] Khairy P, Harris L, Landzberg MJ, et al. Sudden death and defibrillators in transposition of the great arteries with intra-atrial baffles: a multicenter study. *Circ Arrhythm Electrophysiol* 2008;1:250–7.
- [6] Teuwen CP, Ramdjan TT, Gotte M, et al. Time course of atrial fibrillation in patients with congenital heart defects. *Circ Arrhythm Electrophysiol* 2015;8:1065–72.
- [7] Fish FA, Gillette PC, Benson Jr DW. Proarrhythmia, cardiac arrest and death in young patients receiving encainide and flecainide. The Pediatric Electrophysiology Group. *J Am Coll Cardiol* 1991;18:356–65.
- [8] Thorne SA, Barnes I, Cullinan P, Somerville J. Amiodarone-associated thyroid dysfunction: risk factors in adults with congenital heart disease. *Circulation* 1999;100:149–54.
- [9] Koyak Z, Kroon B, de Groot JR, et al. Efficacy of antiarrhythmic drugs in adults with congenital heart disease and supraventricular tachycardias. *Am J Cardiol* 2013;112:1461–7.
- [10] Ho SY, Anderson RH. Conduction tissue in congenital heart surgery. *World J Surg* 1985;9:550–67.
- [11] Ernst S, Babu-Narayan SV, Keegan J, et al. Remote-controlled magnetic navigation and ablation with 3D image integration as an alternative approach in patients with intra-atrial baffle anatomy. *Circ Arrhythm Electrophysiol* 2012;5:131–9.
- [12] Ueda A, Suman-Horduna I, Mantziari L, et al. Contemporary outcomes of supraventricular tachycardia ablation in congenital heart disease: a single-center experience in 116 patients. *Circ Arrhythm Electrophysiol* 2013;6:606–13.
- [13] Blafox AD, Numan MT, Laohakunakorn P, Knick B, Paul T, Saul JP. Catheter tip cooling during radiofrequency ablation of intra-atrial reentry: effects on power, temperature, and impedance. *J Cardiovasc Electrophysiol* 2002;13:783–7.
- [14] Shurrab M, Di Biase L, Briceno DF, et al. Impact of contact force technology on atrial fibrillation ablation: a meta-analysis. *J Am Heart Assoc* 2015;4:e002476.
- [15] Avitall B, Kalinski A. Cryotherapy of cardiac arrhythmia: from basic science to the bedside. *Heart Rhythm* 2015;12:2195–203.
- [16] Perry JC, Boramanand NK, Ing FF. “Transseptal” technique through atrial baffles for 3-dimensional mapping and ablation of atrial tachycardia in patients with d-transposition of the great arteries. *J Interv Card Electrophysiol* 2003;9:365–9.
- [17] Dave AS, Aboulhosn J, Child JS, Shivkumar K. Transcatheter puncture for catheter ablation of atrial tachycardia in a patient with extracardiac Fontan palliation. *Heart Rhythm* 2010;7:413–6.
- [18] Singh SM, Neuzil P, Skoka J, et al. Percutaneous transhepatic venous access for catheter ablation procedures in patients with interruption of the inferior vena cava. *Circ Arrhythm Electrophysiol* 2011;4:235–41.
- [19] Nehgme RA, Carboni MP, Care J, Murphy JD. Transthoracic percutaneous access for electroanatomic mapping and catheter ablation of atrial tachycardia in patients with a lateral tunnel Fontan. *Heart Rhythm* 2006;3:37–43.
- [20] Santangeli P, Di Biase L, Burkhardt JD, et al. Transseptal access and atrial fibrillation ablation guided by intracardiac echocardiography in patients with atrial septal closure devices. *Heart Rhythm* 2011;8:1669–75.
- [21] Mavroudis C, Deal B, Backer CL, Stewart RD. Operative techniques in association with arrhythmia surgery in patients with congenital heart disease. *World J Pediatr Congenit Heart Surg* 2013;4:85–97.
- [22] Khairy P, Van Hare GF, Balaji S, et al. PACES/HRS Expert Consensus Statement on the Recognition and Management of Arrhythmias in Adult Congenital Heart Disease: developed in partnership between the Pediatric and Congenital Electrophysiology Society (PACES) and the Heart Rhythm Society (HRS). Endorsed by the governing bodies of PACES, HRS, the American College of Cardiology (ACC), the American Heart Association (AHA), the European Heart Rhythm Association (EHRA), the Canadian Heart Rhythm Society (CHRS), and the International Society for Adult Congenital Heart Disease (ISACHD). *Heart Rhythm* 2014;11:e102–65.
- [23] Chetaille P, Walsh EP, Triedman JK. Outcomes of radiofrequency catheter ablation of atrioventricular reciprocating tachycardia in patients with congenital heart disease. *Heart Rhythm* 2004;1:168–73.
- [24] Hager A, Zrenner B, Brodherr-Heberlein S, Steinbauer-Rosenthal I, Schreieck J, Hess J. Congenital and surgically acquired Wolff-Parkinson-White syndrome in patients with tricuspid atresia. *J Thorac Cardiovasc Surg* 2005;130:48–53.
- [25] Bar-Cohen Y, Khairy P, Morwood J, Alexander ME, Cecchin F, Berul CI. Inaccuracy of Wolff-Parkinson-white accessory pathway localization algorithms in children and patients with congenital heart defects. *J Cardiovasc Electrophysiol* 2006;17:712–6.
- [26] Wei W, Zhan X, Xue Y, et al. Features of accessory pathways in adult Ebstein’s anomaly. *Europace* 2014;16:1619–25.
- [27] Roten L, Lukac P, de Groot NM, et al. Catheter ablation of arrhythmias in Ebstein’s anomaly: a multicenter study. *J Cardiovasc Electrophysiol* 2011;22:1391–6.
- [28] Upadhyay S, Marie Valente A, Triedman JK, Walsh EP. Catheter ablation for atrioventricular nodal reentrant tachycardia in patients with congenital heart disease. *Heart Rhythm* 2016;13:1228–37.
- [29] Epstein MR, Saul JP, Weindling SN, Triedman JK, Walsh EP. Atrioventricular reciprocating tachycardia involving twin atrioventricular nodes in patients with complex congenital heart disease. *J Cardiovasc Electrophysiol* 2001;12:671–9.
- [30] Akca F, Bauernfeind T, Witsenburg M, et al. Acute and long-term outcomes of catheter ablation using remote magnetic navigation in patients with congenital heart disease. *Am J Cardiol* 2012;110:409–14.
- [31] Anguera I, Dallaglio P, Macias R, et al. Long-term outcome after ablation of right atrial tachyarrhythmias after the surgical repair of congenital and acquired heart disease. *Am J Cardiol* 2015;115:1705–13.
- [32] Correa R, Sherwin ED, Kovach J, et al. Mechanism and ablation of arrhythmia following total cavopulmonary connection. *Circ Arrhythm Electrophysiol* 2015;8:318–25.

- [33] Correa R, Walsh EP, Alexander ME, et al. Transbaffle mapping and ablation for atrial tachycardias after mustard, senning, or Fontan operations. *J Am Heart Assoc* 2013;2:e000325.
- [34] de Groot NM, Atary JZ, Blom NA, Schalij MJ. Long-term outcome after ablative therapy of postoperative atrial tachyarrhythmia in patients with congenital heart disease and characteristics of atrial tachyarrhythmia recurrences. *Circ Arrhythm Electrophysiol* 2010;3:148–54.
- [35] Drago F, Russo MS, Marazzi R, Salerno-Uriarte JA, Silvetti MS, De Ponti R. Atrial tachycardias in patients with congenital heart disease: a minimally invasive simplified approach in the use of three-dimensional electroanatomic mapping. *Europace* 2011;13:689–95.
- [36] Hebe J, Hansen P, Ouyang F, Volkmer M, Kuck KH. Radiofrequency catheter ablation of tachycardia in patients with congenital heart disease. *Pediatr Cardiol* 2000;21:557–75.
- [37] Kannankeril PJ, Anderson ME, Rottman JN, Wathen MS, Fish FA. Frequency of late recurrence of intra-atrial reentry tachycardia after radiofrequency catheter ablation in patients with congenital heart disease. *Am J Cardiol* 2003;92:879–81.
- [38] Lukac P, Pedersen AK, Mortensen PT, Jensen HK, Hjortdal V, Hansen PS. Ablation of atrial tachycardia after surgery for congenital and acquired heart disease using an electroanatomic mapping system: which circuits to expect in which substrate? *Heart Rhythm* 2005;2:64–72.
- [39] Mah DY, Alexander ME, Cecchin F, Walsh EP, Triedman JK. The electroanatomic mechanisms of atrial tachycardia in patients with tetralogy of Fallot and double outlet right ventricle. *J Cardiovasc Electrophysiol* 2011;22:1013–7.
- [40] Moore JP, Shannon KM, Fish FA, et al. Catheter ablation of supraventricular tachyarrhythmia after extracardiac Fontan surgery. *Heart Rhythm* 2016;13:1891–7.
- [41] Seiler J, Schmid DK, Irtel TA, et al. Dual-loop circuits in postoperative atrial macro re-entrant tachycardias. *Heart* 2007;93:325–30.
- [42] Triedman JK, Alexander ME, Love BA, et al. Influence of patient factors and ablative technologies on outcomes of radiofrequency ablation of intra-atrial re-entrant tachycardia in patients with congenital heart disease. *J Am Coll Cardiol* 2002;39:1827–35.
- [43] Yap SC, Harris L, Silversides CK, Downar E, Chauhan VS. Outcome of intra-atrial re-entrant tachycardia catheter ablation in adults with congenital heart disease: negative impact of age and complex atrial surgery. *J Am Coll Cardiol* 2010;56:1589–96.
- [44] Schwartzman D, Callans DJ, Gottlieb CD, Dillon SM, Movsowitz C, Marchlinski FE. Conduction block in the inferior vena caval-tricuspid valve isthmus: association with outcome of radiofrequency ablation of type I atrial flutter. *J Am Coll Cardiol* 1996;28:1519–31.
- [45] Hsieh MH, Tai CT, Chiang CE, et al. Recurrent atrial flutter and atrial fibrillation after catheter ablation of the cavotricuspid isthmus: a very long-term follow-up of 333 patients. *J Interv Card Electrophysiol* 2002;7:225–31.
- [46] Ganesan AN, Shipp NJ, Brooks AG, et al. Long-term outcomes of catheter ablation of atrial fibrillation: a systematic review and meta-analysis. *J Am Heart Assoc* 2013;2:e004549.
- [47] Mallidi J, Nadkarni GN, Berger RD, Calkins H, Nazarian S. Meta-analysis of catheter ablation as an adjunct to medical therapy for treatment of ventricular tachycardia in patients with structural heart disease. *Heart Rhythm* 2011;8:503–10.
- [48] Pothineni NV, Deshmukh A, Padmanabhan D, et al. Complication rates of ventricular tachycardia ablation: comparison of safety outcomes derived from administrative databases and clinical trials. *Int J Cardiol* 2015;201:529–31.
- [49] de Groot NM, Zeppenfeld K, Wijffels MC, et al. Ablation of focal atrial arrhythmia in patients with congenital heart defects after surgery: role of circumscribed areas with heterogeneous conduction. *Heart Rhythm* 2006;3:526–35.
- [50] Moore JP, Russell M, Mandapati R, Aboulhosn JA, Shannon KM. Catheter ablation of tachycardia arising from the pulmonary venous atrium after surgical repair of congenital heart disease. *Heart Rhythm* 2015;12:297–304.
- [51] Suman-Horduna I, Ernst S. Ablation of atrial tachycardia after Mustard and Senning surgeries for d-transposition of the great arteries. *Prog Pediatr Cardiol* 2012;34:75–8.
- [52] Kirsh JA, Walsh EP, Triedman JK. Prevalence of and risk factors for atrial fibrillation and intra-atrial reentrant tachycardia among patients with congenital heart disease. *Am J Cardiol* 2002;90:338–40.
- [53] Nitta T, Sakamoto S, Miyagi Y, Fujii M, Ishii Y, Ochi M. Reentrant and focal activations during atrial fibrillation in patients with atrial septal defect. *Ann Thorac Surg* 2013;96:1266–72.
- [54] Frankel DS, Shah MJ, Aziz PF, Hutchinson MD. Catheter ablation of atrial fibrillation in transposition of the great arteries treated with mustard atrial baffle. *Circ Arrhythm Electrophysiol* 2012;5:e41–3.
- [55] Kirubakaran S, Rajani R, Linton N, Kieseewetter C, Anderson D, O'Neill M. Catheter ablation for persistent atrial fibrillation in a patient with previous repair of total anomalous pulmonary venous connection. *Circ Arrhythm Electrophysiol* 2013;6:e54–5.